



Dental Disease in Guinea Pigs

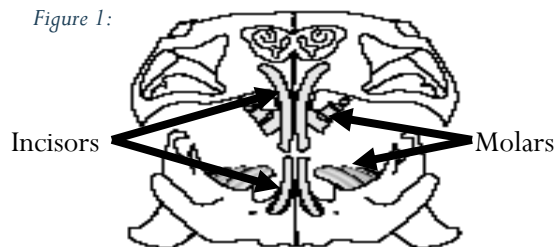
Introduction

As hystricomorph rodents, guinea pigs have both continuously growing incisors (front teeth) and molars (chewing or back teeth). This continual growth allows them to eat fibrous and abrasive foods in their natural environment. Normally, the anatomical placement of the teeth causes each side to wear down its opposing side, keeping everything in good balance. However, if this balance is disrupted, then ongoing problems can occur.

Guinea Pig Dentition

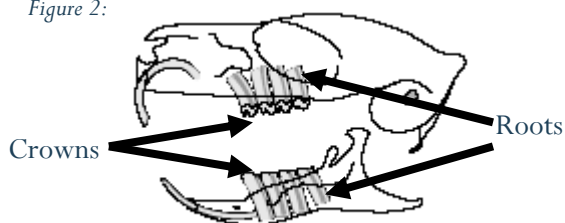
The dental formula in a guinea pig is $2x(1/1, C0/0, P1/1, M3/3)$. This means that in each quarter of the jaw (upper and lower, left and right) has one incisor, no canines, one premolar and 3 molar teeth. The premolars and molars together are called the 'cheek teeth'. The occlusal (chewing) surfaces are not perpendicular, but rather meet up on an angle. The upper teeth tend to be rotated slightly outward, towards the cheeks, whereas the lower teeth tend to be rotated slightly inward, toward the tongue. This is shown in Figure 1.

Figure 1:



From an evolutionary perspective, guinea pigs have evolved to live on a poor quality, fibrous and abrasive diet. This type of diet keeps all of the continually growing teeth well worn, and keeps the chewing muscles well developed. Figure 2 shows a lateral view of a guinea pig head and teeth. Each tooth has a crown (part above the gum line) and a root (embedded in the jaw and below the gum line).

Figure 2:



Dental Disease

When the teeth move out of occlusion (mis-alignment of the chewing surface), which can happen for a number of reasons, the continual growth will tend to create spurs and hooks on the outside of the upper teeth (pushing into the cheeks) and on the inside of the lower teeth (pushing into the tongue). In fact, in advanced disease, the lower premolar teeth can actually grow together and meet, bridging the tongue and impeding swallowing! Additionally, as dental disease progresses, the teeth may start to grow at different rates, resulting in a 'wave' appearance to the occlusal (chewing) surface of the crowns. The tooth roots can also start to grow into the bone, pushing on the mandible (lower jaw) or causing tear duct or eye problems (upper jaw). Tooth root elongation can lead to chronic bone pain.

Clinical Signs of Dental Disease

Guinea pigs with dental disease are typically extremely interested in food, but reluctant to eat. They may drop food while chewing, refuse harder food types, dribble, or have difficulty chewing and swallowing. There is usually weight loss, which may be accompanied by diarrhoea, constipation or depression. Dental disease is very common in guinea pigs, so owners should be vigilant in order to treat early, before the development of secondary problems.

Why does it happen?

There are several causes of dental disease, which may occur singly or together:

1. Insufficient fibre/abrasiveness in the diet. Low fibre diets require less chewing, which leads to inadequate wear on the continually growing molar teeth. These teeth then develop crown overgrowth, which alters the guinea pig's chewing movement and can eventually lead to changes in tooth alignment.
2. Metabolic bone disease. Healthy bones require calcium, vitamin D and ultraviolet light to stay strong. Guinea pigs with poor access to sunlight, or on diets with low calcium and vitamin D, will develop softening of the bones. Normal chewing pressure can then cause the tooth alignment to alter, leading to dental disease.
3. Vitamin C deficiency. Vitamin C is involved in bone metabolism, maintenance of the periodontal ligament as well in the maintenance of many other tissues. Guinea pigs with no Vitamin C supplementation and diets deficient in vitamin C, can lead to loosening of the teeth within their sockets, and malalignment.
4. Genetics. Some strains of guinea pigs appear to develop dental disease much more commonly than others, so there appears to be a hereditary element to dental disease.

Treatment

Once a guinea pig has developed dental disease, there is no way to reposition the teeth into a normal alignment. Treatment aims at restoring comfort and the ability to eat, by removing spurs and hooks with a dental burr under general anaesthesia. Usually, radiographs of the mouth are taken at the same time, allowing staging of the disease process. It is important to be aware that the clinical signs of dental disease WILL recur at some point, because the tooth growth will continue to be at an abnormal angle, eventually resulting in spurs and hooks. The guinea pig will then show clinical signs again, and will need to have the dental procedure repeated in order to keep them eating, more comfortable, and healthy.

